

Idiopathic IgA Nephropathy: Pathogenesis, Histopathology, and Therapeutic Options

James A. Tumlin,* Michael P. Madaio,[†] and Randolph Hennigar[‡]

*Clinical Research Division, Southeast Renal Associates, Charlotte, North Carolina; [†]Nephrology and Kidney Transplantation Section, Temple University, Philadelphia, Pennsylvania; and [‡]Department of Pathology, Emory University, Atlanta, Georgia

IgA nephropathy is one of the most common causes of glomerulonephritis in the world. Proliferative and crescentic forms of IgA are found in up to 30% of cases and are associated with nephrotic-range proteinuria, accelerated hypertension, and accelerated decline toward ESRD. Despite its prevalence and clinical importance, there is no unifying nomenclature or consensus for the treatment of specific histologic subgroups. As a consequence, the development of clinically effective treatment regimens for IgA nephropathy have lagged behind other, less common forms of glomerulonephritis. Herein is reviewed the pathogenesis and histologic subtypes of IgA nephropathy and how conventional and immunosuppressive therapies have an impact on renal survival and recurrence rates. The use of known clinical risk factors for disease progression in conjunction with specific histologic features can be a guide to both induction and consolidation therapies for individual patients with IgA nephropathy.

Clin J Am Soc Nephrol 2: 1054-1061, 2004. doi: 10.2215/CJN.04351206

Epidemiology and Natural History

IgA nephropathy (IgAN) is considered to be the most common form of glomerulonephritis in the world (1). Although IgAN is prevalent in all ethnic groups, Japan and Korea have some of the highest recorded incidences. For example, approximately 50% of new cases of glomerulonephritis and 40% of all ESRD in Japan are due to IgAN. This is in contrast to the United States and Western Europe, where IgAN accounts for 10 and 30% of glomerulonephritis, respectively (2). Although these disparities may reflect differences in public health awareness or the willingness of nephrologists to perform diagnostic biopsies, certain populations seem to have a genetic predisposition to the development of IgAN (1).

The clinical presentation of a typical flair includes the development of painless hematuria concurrent with the onset of a viral pharyngitis, gastroenteritis, or pneumonia. Approximately 30 to 40% of patients with IgAN will present with gross hematuria and renal dysfunction. Praga *et al.* (3) reviewed the clinical course of 29 patients with gross hematuria secondary to IgAN and demonstrated that 37% developed transient renal failure. Although early renal dysfunction was more common in patients with gross hematuria, complete recovery was experienced by all 29 patients. These results are consistent with previous observations that patients with intermittent gross hematuria do not develop proteinuria and generally have a better overall prognosis (4).

IgAN has been generally regarded as a benign form of glo-

merulonephritis, with approximately 25 to 30% of patients reaching ESRD after 10 yr (5). Clinical risk factors linked to progressive IgA disease include hypertension, proteinuria >1.0 g/24 h, male gender, and persistent microscopic hematuria, (4–6).

Clinical Presentation of Crescentic/Proliferative IgAN

Specific histologic features are associated with a poor prognosis, including cellular crescents, endocapillary proliferation, and karyorrhexis. It is interesting that these histologic signs often do not correlate with existing clinical risk factors (7). For example, Almartine *et al.* (8) examined the biopsies of 282 patients with IgAN and demonstrated that the presence of crescents did not correlate with hypertension or proteinuria. In contrast, Welch and colleagues (9–11) reported that >75% of patients with IgAN and endocapillary proliferation had hypertension at presentation, whereas up to 20% presented with accelerated hypertension (mean arterial pressure >150 mmHg). Moreover, Tumlin *et al.* (12,13) reviewed the clinical presentation of 20 patients who had IgAN with at least 10% cellular crescents and demonstrated that all had hypertension (mean arterial pressure >90 mmHg) with >1.0 g of proteinuria, and an additional 33% presented with nephrotic-range proteinuria.

Pathogenesis of IgAN: Role of Polymeric IgA

IgAN is an immune complex glomerulonephritis that involves intense deposition of dimeric and polymeric forms of IgA1 within the mesangium of the glomerulus (14). In general, glomeruli with the largest number of IgA complexes exhibit the highest levels of neutrophilic infiltration and mesangial hypercellularity, suggesting a causal link between IgA deposition

Published online ahead of print. Publication date available at www.cjasn.org.

Address correspondence to: Dr. James A. Tumlin, Clinical Research Division, Southeast Renal Associates, 2301 W. Morehead Street, Charlotte, NC 28208. Phone: 704-927-1757; Fax: 704-334-7669; E-mail: jtumlin@emory.edu

and the development of glomerular inflammation (15). The pathophysiologic mechanisms that predispose to the deposition of IgA complexes in the glomerular mesangium are unknown. Elevated levels of IgA1 and IgA1-containing circulating complexes are found in sera of most patients with IgAN (1). The presence of J chains in the glomeruli of patients with IgAN has led many investigators to conclude that polymeric IgA is the predominate form in mesangial deposits (16). Moreover, the observation that IgA complexes resolve when kidneys of patients with IgAN are transplanted into patients without IgAN suggests that mesangial complexes are the result of deposition as opposed to *in situ* synthesis (16).

Van Der Boog *et al.* (17) used recombinant CD89/Fc γ receptor to isolate polymeric IgA from 51 patients with IgAN and 21 healthy control subjects. Whereas the quantity of circulating polymeric IgA was increased in patients with IgAN, the amount of polymeric IgA eluted from mesangial deposits did not differ between patients and control subjects. Moreover, subsequent studies failed to demonstrate higher amounts of polymeric IgA in patients with persistent hematuria or significant levels of proteinuria (>1.0 g/24 h) (18). These observations suggest that although polymeric forms of IgA may play a role in the pathogenesis of IgAN, it is insufficient to generate the full expression of the disease. Because mesangial cells express CD89 (Fc) receptors, others have suggested that accumulation of IgA complexes within the mesangium is enhanced by Fc receptor binding. Moreover, the interactions between IgA molecules and CD89 receptors could stimulate the production of proinflammatory cytokines, leading to matrix expansion and additional glomerular inflammation (19).

Aberrant Glycosylation of IgA

Recent studies found that polymeric IgA complexes with reduced glycosylation at the hinge region of the molecule exhibit higher avidity for binding to mesangial cells (16). Two prevailing theories have been postulated to explain this observation. The first involves the hypothesis that aberrant glycosylation of IgA1 molecules facilitates formation of polymeric IgA and enhances mesangial deposition. Serine and threonine structures concentrated near the hinge region of the molecule un-

dergo O-glycosylation with oligosaccharides that include N-acetyl-galactosamine (GalNAc) and N-acetylneuraminic acid (NANA) (17). The importance of O-glycosylation to the formation of mesangial IgA deposits is illustrated by the work of Sano *et al.* (15), who isolated IgA1 antibodies from normal individuals and demonstrated that enzymatic removal of all complex oligosaccharides from the hinge region significantly enhanced IgA deposition within the mesangium. Allen and colleagues (20,21) demonstrated that the amount of GalNAc-deficient IgA1 in the kidney was significantly greater than that in serum. Moreover, Hiki *et al.* (22) found that IgA eluted from the biopsies of patients with active IgAN was more likely to have reduced glycosylation compared with patients with inactive disease. More specific, Xu and Zhao (23) quantified the amount of NANA and GalNAc forms of IgA₁ in the serum of 107 patients with biopsy-proven IgAN and demonstrated that IgA molecules that were deficient in NANA or GalNAc glycosylation were more likely to be eluted from patients with proliferative disease.

IgG Anti-IgA1 Autoantibodies

The reduction in glycosylation at the hinge region not only facilitates formation of polymeric IgA1 but also contributes to its recognition as a neoantigen and the subsequent formation of IgG autoantibodies against Gal-deficient IgA1 molecules. Subsequently, either Gal-deficient IgA1 or IgG autoantibodies against IgA1 bind to CD89 (FcR) expressed on the surface of mesangial cells, leading to production of proinflammatory cytokines, recruitment of circulating cells, and overt inflammation. More recently, polymeric IgA was shown to activate the alternative complement pathway through binding of mannose-binding lectin (20). In this regard, polymeric IgA can recruit additional inflammatory cells through the binding of CD89 receptors and complement activation *via* the mannose-binding lectin-alternative pathway (20).

IgA Classification and Nomenclature

In its "classic" presentation, IgAN is characterized by a mesangiopathic process with expansion of the mesangial matrix, immunofluorescent staining for IgA, and the proliferation of

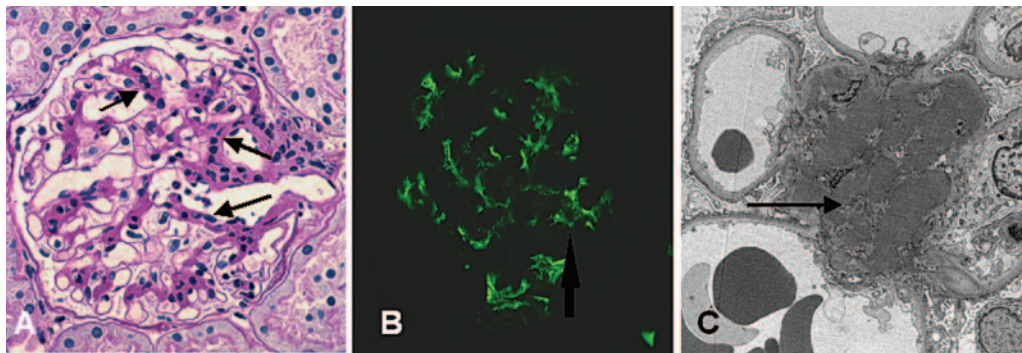


Figure 1. (A) Hematoxylin-eosin stain demonstrating expansion of mesangial matrix with mesangial hypercellularity (bold arrows). (B) Immunofluorescent microscopy for IgA deposition. Staining for IgA immune complexes within glomerular mesangium. (C) Electron microscopy significant for expansion of mesangial matrix and presence of large mesangial dense deposits (arrow).

mesangial cells (Figure 1). The histologic presentation of IgAN is not limited to these findings but like other immune complex glomerulonephritides can exhibit more aggressive histology, including crescents, karyorrhexis, and endocapillary proliferation. In an attempt to provide a classification system to IgA disease, Haas (7) reviewed the biopsies of 244 cases of IgAN and classified patients according to the presence or absence of specific histologic findings. Patients were divided into five subclasses on the basis of the degree of mesangial cell proliferation (Figure 2A), the presence of endocapillary proliferation, and the percentage of cellular crescents.

Proliferative IgAN

Class III and class IV disease represent the proliferative forms of IgAN and are analogous to the World Health Organization's classification of proliferative lupus nephritis. Patients with class III and Class IV demonstrate the presence of endocapillary proliferation (Figure 2, B and C). The presence of crescents or karyorrhexis is also a significant feature of class III/IV disease but is not required for this designation. To determine the clinical utility of this classification, Haas (7) correlated IgA class with clinical outcomes and demonstrated that patients with class IV disease had a 45% chance of developing ESRD within

5 yr (Figure 2C). Recent studies have raised the question of whether the Haas classification has sufficient sensitivity for clinical decision making (13). For example, patients require >50% cellular crescents before being labeled as having class IV IgA disease. However, recent prospective studies showed that 40% of patients with as little as 10% cellular crescents will progress to ESRD within 3 yr (13).

The incidence of proliferative IgAN is unknown. A review of the literature reveals that the worldwide incidence of crescentic IgAN ranges between 8 and 36% (Figure 2D) (1,24–26). Indeed, up to 10% of patients with IgAN exhibit acute necrotizing lesions (*i.e.*, fibrinoid necrosis) in glomeruli (27) (Figure 2E). These lesions tend to be focal and segmental and accompanied by karyorrhexis and crescents. Hisano *et al.* (28) reported that up to 11% of Japanese children present with diffuse endocapillary proliferation (>80% of glomeruli), suggesting that more aggressive forms of the disease are more prevalent among Asian populations. The incidence of extracapillary proliferation is also poorly documented. Tang *et al.* (29) retrospectively examined 2186 biopsies from patients with IgA disease and documented that up to 2% of patients had cellular crescents in >50% of glomeruli.

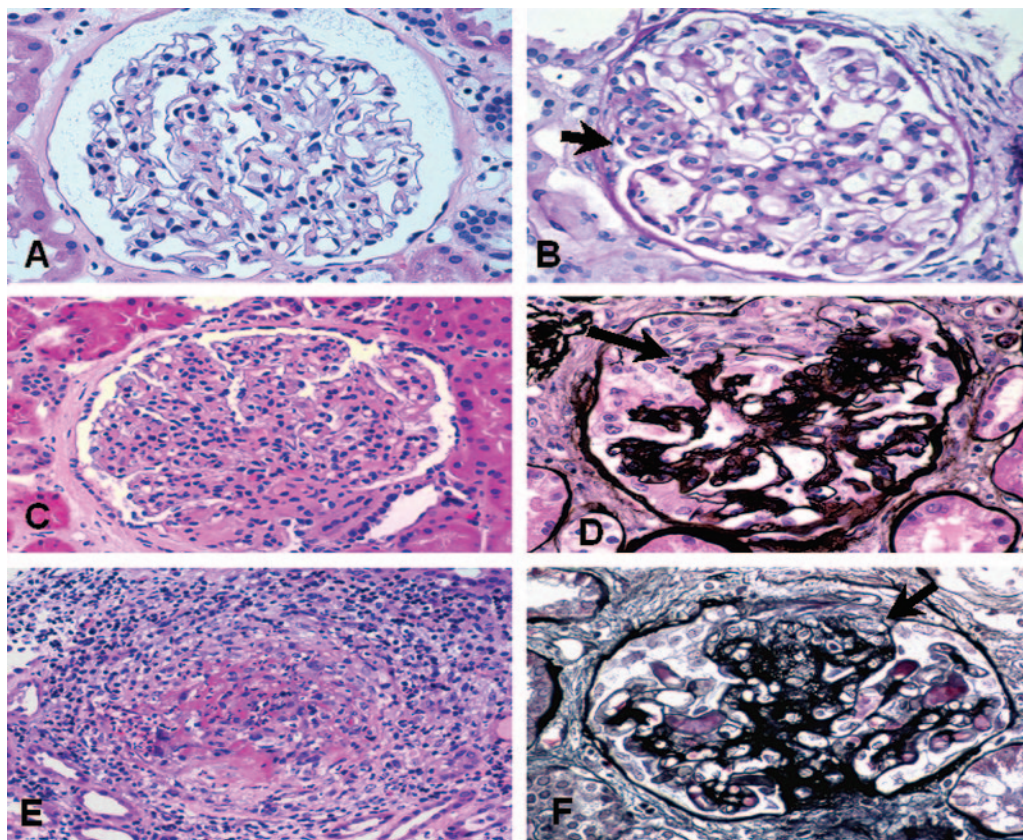


Figure 2. (A) Hematoxylin-eosin stain demonstrating mesangial hypercellularity and matrix expansion. (B) Hematoxylin-eosin stain with mesangial cell hypercellularity and focal area of endocapillary proliferation (bold arrow). (C) Hematoxylin-eosin stain demonstrating diffuse endocapillary proliferation and mesangial hypercellularity. Haas class IV IgA nephropathy. (D) Hematoxylin-eosin-silver stain demonstrating epithelial cell crescent with partial collapse of glomerular tuft. (E) Hematoxylin-eosin stain demonstrating diffuse endocapillary proliferation and fibrinoid necrosis. (F) Silver stain demonstrating incipient crescent and focal glomerular tuft adhesion to Bowman's capsule.

Treatment of Nonproliferative IgAN

The pathologic manifestations of IgAN are broad and can range from mild mesangial hypercellularity to a rapidly progressive glomerulonephritis with fulminate crescents and endocapillary proliferation (7,30). The prognostic significance of specific histologic lesions is unknown in part because of the lack of a uniform nomenclature for specific IgA subgroups (8–10,31–35). Moreover, the absence of defined subgroups impedes the study of their natural history and the subsequent development of specific clinical guidelines. Currently, the clinical decision to treat a patient who has IgAN with angiotensin-converting enzyme inhibitors (ACEI) alone or to add steroids or fish oil supplements largely depends on the presence of clinical signs associated with a poor prognosis. For example, patients with minimal proteinuria (*e.g.*, <500 mg/24 h) may be limited to ACEI therapy, whereas patients with high-grade or nephrotic-range proteinuria may have steroid hormones added to their treatment.

Nonimmunosuppressive Therapy

Although numerous studies have shown the efficacy of angiotensin receptor blockers (ARB) and ACEI in the treatment of IgAN, many of these studies were limited to patients who presented with an overall favorable prognosis. However, two recent studies examined the effect of ACEI on proteinuria and disease progression in patients with hypertension and high-grade proteinuria. For example, Praga *et al.* (36) prospectively randomly assigned 44 patients with IgAN to enalapril or conventional antihypertensive agents and demonstrated that ACE inhibition significantly lowered proteinuria by 55%. Moreover, after 4 yr of ACEI therapy, 100% of patients in the treatment group had intact renal function, defined as <50% rise in serum creatinine compared with 70% among the control subjects. These renal survival rates are comparable to those observed by Pozzi *et al.* (37) after corticosteroid therapy, suggesting that ACEI/ARB therapy may be an alternative to immunosuppressive therapy. Horita *et al.* (38) treated 31 patients who had crescentic IgAN with ACEI/ARB combinations and demonstrated a significant reduction in proteinuria. However, the effect of combination therapy on long-term renal survival could not be determined because of the short duration of therapy and follow-up. Moreover, the failure to examine patient populations with similar degrees of renal pathology limits the ability to compare different treatment regimens.

The use of omega-3 fish oil supplements is a well-established adjunctive therapy for reducing proteinuria and slowing the progression of IgAN (39–41). In a prospective study of 55 patients with IgAN and nephrotic-range proteinuria, Donadio *et al.* (39) found that high-dosage (12 g) omega-3 fatty acid supplements significantly reduced proteinuria and prolonged renal survival. Subsequent studies demonstrated that a similar protective effect could be observed using lower (4.0 g) dosages of fish oil supplements (40). Although omega-3 fatty acids were able to lower urinary protein beyond the effect of ACEI, it is unknown whether a similar effect could be seen in patients with proliferative forms of IgAN. In a placebo control study of 96 pediatric patients with biopsy-proven IgAN, Hogg *et al.* (41)

failed to demonstrate any protective effect of long-term steroids (12 mo) or omega-3 fatty acid supplements (24 mo). The lack of efficacy observed by Hogg *et al.* may reflect the higher proportion of patients with proliferative forms of IgAN. For example, up to 20% of patients had histologic evidence of endocapillary proliferation, and another 6% had cellular or fibrocellular crescents (42).

Steroid Therapy for Nonproliferative IgAN

The efficacy of steroid hormones in the treatment of IgAN remains controversial. This is due in part to differences in trial design, the slow progression of IgAN, and the failure to study patients with similar degrees of disease severity (35). Kobayashi *et al.* (43) studied 46 patients with IgAN and compared the effects of conventional therapy with 18 mo of steroids on proteinuria and renal survival. After 5 yr, there was a modest but NS reduction in renal survival among the control group (100% steroid *versus* 85% control), whereas more prolonged follow-up demonstrated that 61% of the control group compared with 20% of the steroid group progressed to ESRD. In a larger study, Pozzi *et al.* (37) randomly assigned 86 patients with IgAN to tight BP control (<140/90) with ACEI or ARB *versus* 6 mo of combined oral and intravenous steroids. Although there was no improvement in renal survival after 2 yr, only a single patient (2.3%) in the steroid group doubled serum creatinine after 7 yr of follow-up compared with 13 (30.2%) among the control group ($P < 0.005$). Using multivariate regression analysis, Pozzi *et al.* demonstrated that patients with <1 g of proteinuria after 6 mo of therapy were significantly less likely to develop progressive IgAN (relative risk 0.58; $P < 0.016$). In contrast, Katafuchi *et al.* (44) randomly assigned 90 patients to 2 yr of steroid therapy or conventional treatment and compared the effects on proteinuria and renal survival. Although steroids significantly reduced proteinuria (2.27 to 0.34 g/24 h), long-term follow-up failed to demonstrate any protective effect of steroids on renal function.

Proliferative IgAN: Efficacy of Steroid Therapy

To determine the role of immunosuppressive therapy in patients with proliferative forms of IgAN, Lai *et al.* (45) examined the effects of short-term steroid therapy (4 mo) on proteinuria in 34 patients with proliferative and nonproliferative forms of IgAN. In patients with nonproliferative disease, proteinuria fell from a mean of from 8.1 to 1.2 g proteinuria/24 h ($P < 0.001$), whereas clinical symptoms of the nephrotic syndrome were reduced in seven of eight patients. Short-term steroid therapy seemed to be effective in patients with proliferative forms of IgAN. Despite the presence of up to 30% cellular crescents (group III), 4 mo of steroid therapy reduced proteinuria by a mean of 44% in eight of 10 patients ($P < 0.002$). Moreover, Lai *et al.* found that even a short course of steroid therapy seemed to stabilize renal function. For example, 3.5 yr after treatment, creatinine clearance in the steroid-treated group increased from 68 to 74 ml/min, whereas clearance in the control group fell from 68 to 64 ml/min.

Table 1 shows the outcomes of 370 patients who were enrolled in nine different trials that compared steroid therapy

Table 1. Prospective trials of steroid therapy in IgAN^a

Reference	No. of Patients	Study Type	Target BP ACE/ARB	First End Point	% of End Points (P)	Steroids		Mean Prot (g/24 h)	Duration of F/U (Yr)	% of Crescents	ΔProtein Steroid Rx (g/24 h)
						Oral (Mo)	Intravenous				
Pozzi <i>et al.</i> (37)	86	Prosp Rand	<140/90 +/+	Doubling SCr	2.3/30.2 0.0003	+	+	1.8	10	7	Baseline 2.0 F/U 0.8
Katafuchi <i>et al.</i> (44)	90	Prosp Rand	<130/80 +/-	ΔUP/Cr %ESRD	0.0034 NS	+	-	1.65	5	10	Baseline 2.3 F/U 1.3
Kobayashi <i>et al.</i> (43)	53	Prosp	<150/90	Renal survival	84/34	+	-	1.4	10	NR	Baseline 1.4
Lai <i>et al.</i> (45)	34	Prosp Rand	<150/90 NR	ΔProt ΔCr	0.001 0.02	+	-	6.5	3.5	30	F/U 0.8
Shoji <i>et al.</i> (51)	20	Prosp Rand	<135/85 -/-	ΔProt ΔCr	0.05 NS	+	-	0.75	1	4	Baseline 6.5 F/U 2.3
Kuriki <i>et al.</i> (38)	16	Prosp Open	<140/90 -/-	ΔProt % Sclerosis	0.003 0.005	+	+	1.6	1	30	Baseline 0.75 F/U 0.3
Waldo (57)	13	Prosp Open	NR	Renal function ΔProt	NS 0.03	+	-	1.0	1	NR	Baseline 1.0 F/U 0.3
Hotta <i>et al.</i> (52)	35	Prosp Open	<130/80 NR/NR	ΔProt % Sclerosis	0.001 0.001	+	+	1.0	1	91	Baseline 1.6 F/U 0.3
Haramaki (58)	23	Prosp Open	NR	ΔProt ΔTGF-β	<0.05	+	-	0.6	1	NR	Baseline 0.6 F/U 0.4

^aACEI, angiotensin-converting enzyme inhibitors; ARB, angiotensin receptor blockers; CR, creatinine; F/U, follow-up; IgAN, IgA nephropathy; NR, not recorded; Open, open label; Prosp, prospective; Prot, protein; Rand, randomized; SCr, serum creatinine; UP, urinary protein.

with dipyridamole, tonsillectomy, or no treatment. Of the nine trials, two were prospective, randomized trials; the remaining seven were prospective, open-label studies. Follow-up was broad, ranging from 1 mo to 10 yr. The mean proteinuria for all nine trials was 1.81 g/24 h. The histopathology was not listed in each study, but the majority listed the presence of cellular crescents.

Proliferative IgAN: Combination Steroid and Alkylating Agents

Despite the lack of consensus regarding the prognostic significance of crescents and other proliferative lesions, many investigators have chosen to treat more aggressive forms of IgAN with steroids, cyclophosphamide, or other alkylating agents. For example, Ballardie and Roberts (46) treated 38 patients who had progressive IgAN with 3 mo of oral cyclophosphamide in combination with 2 yr of methylprednisolone. A clear renal preservation was found among patients who received combination steroids and cyclophosphamide. Renal survival in the combination group was 82, 82, 72, and 72% at 2, 3, 4, and 5 yr, respectively. In contrast, patients who were randomly assigned to steroids alone experienced a significant decline in renal function, with only 68, 47, 26, and 6% of patients having intact renal function at the end of 5 yr. In a smaller study, Roccatello *et al.* (47) treated 12 patients who had florid, crescentic IgAN (60 to 80% crescents) with pulse Solu-Medrol (1.0 g) and oral cyclophosphamide (1.5 mg/kg) for 8 wk. Again, after 5 yr of follow-up, patients who received steroids and cyclophosphamide had a 91% renal survival compared with 37% among untreated control subjects. Last, Tumlin *et al.* (12) treated 20 patients who had >10% crescents on initial biopsy with pulse Solu-Medrol and intravenous cyclophosphamide and found that after 36 mo of follow-up, serum creatinine and 24-h urinary protein were significantly improved compared with baseline. Moreover, repeat kidney biopsies performed after 6 mo of therapy demonstrated complete resolution of crescents and proliferative lesions.

A number of small studies have examined the efficacy of mycophenolate mofetil (MMF) as an alternative therapy to cyclophosphamide. Tang *et al.* (48) randomly assigned 40 patients to 6 mo of MMF compared with conventional therapy including tight BP control (<125/85) with ACEI or ARB therapy. Patients who were randomly assigned to MMF experienced a 40% reduction in proteinuria at the end of 72 wk of follow-up, whereas patients who received conventional therapy developed worsening proteinuria (+20%). However, the change in creatinine clearance was not different between the two groups. In a randomized, prospective, placebo-controlled trial, Maes *et al.* (49) treated 34 patients who had IgAN with MMF (2.0 g/d) for 3 yr. In contrast to Tang *et al.*, MMF did not reduce proteinuria or improve renal survival, compared with ACEI and tight BP control.

Effect of Immunosuppressive Therapy on Renal Histology

To determine whether steroids and other immunosuppressive therapies improve renal histology, many investigators have performed surveillance renal biopsies after the completion of therapy. For example, Harmankaya *et al.* (50) found that

prednisolone and azathioprine reduced mesangial cell proliferation in 50% of patients. Moreover, there was a reduction in glomerulosclerosis, tubular atrophy, or interstitial fibrosis. In a similar study, Shoji *et al.* (51) compared the effects of steroid therapy with dipyridamole in 21 patients with proliferative IgAN. After 1 yr of therapy, repeat biopsies were performed in 19 of 21 patients and demonstrated that both cellular and fibrocellular crescents were significantly reduced. Hotta *et al.* (52) demonstrated that tonsillectomy and pulse methylprednisolone eliminated cellular crescents in 32 (91%) of 35 patients. Last, Tumlin and Hennigar (13) performed repeat renal biopsies in 20 patients after 6 mo of intravenous cyclophosphamide and steroid therapy. Whereas all patients had a minimum of 10% crescents, endocapillary proliferation, or karyorrhexis at study entry, none had residual proliferative lesions after the completion of therapy. It is interesting that despite aggressive and prolonged steroid therapy (36 mo), approximately 15% of patients experienced a recurrence of proliferative IgAN with 3 yr.

Conclusions

Despite limitations within the existing literature, reasonable clinical decisions regarding therapy for IgAN can be made on the basis of a patient's individual clinical and histologic risk factors. For patients with hypertension but low-grade (<1.0 g) proteinuria and mild histologic changes (*i.e.*, mesangial expansion with or without mesangial hypercellularity), the literature supports conservative therapy using combination ACEI/ARB therapy to achieve tight BP control (<125/85). Prospective studies have demonstrated that for patients with higher grades of proteinuria, omega-3 fatty supplements can slow progression of renal disease and affords patients a survival advantage. Patients with accelerated hypertension or nephrotic-range proteinuria or patients with proliferative lesions on renal biopsy should be considered for immunosuppressive therapy. This can include pulse or oral steroids with or without the addition of alkylating agents; both of which have been shown to be safe and effective in proliferative IgAN (13,46,53–56). Current studies do not support the use of MMF in the primary treatment of IgAN but may play a role in long-term suppressive therapy (41). Establishing effective therapies for IgAN will require the creation of an international consensus on subgroup definitions, which will in turn improve our understanding of the natural history of IgAN. These data will be indispensable in the design of trials that will answer the risk–benefit questions of aggressive treatment for specific subgroups of IgAN.

Disclosures

None.

References

1. D'Amico G: The commonest glomerulonephritis in the world: IgA nephropathy. *Q J Med* 64: 709–727, 2001
2. Galla J: IgA nephropathy. *Kidney Int* 47: 377–387, 1995
3. Praga M, Guitierrez-Millet V, Navas J, Ruilope LM, Morales JM, Alcazar JM, Bello I, Rodicio JL: Acute worsening of renal function during episodes of macroscopic hematuria in IgA nephropathy. *Kidney Int* 28: 69–74, 1985

4. Donadio J, Grande J: Immunoglobulin A nephropathy: A clinical perspective. *J Am Soc Nephrol* 8: 1324-1332, 1997
5. D'Amico G: Natural history of idiopathic IgA nephropathy: Role of clinical and histological prognostic factors. *Am J Kidney Dis* 36: 227-237, 2001
6. Descamps-Latscha B, Witko-Sarsat V, Nguyen-Khoa T, Nguyen AT, Gausson V, Mothu N, Cardoso C, Noel LH, Guerin AP, London GM, Jungers P: Early prediction of IgA nephropathy progression: Proteinuria and AOPP are strong prognostic markers. *Kidney Int* 66: 1606-1612, 2004
7. Haas M: Histological subclassification of IgA nephropathy: A clinicopathologic study of 244 cases. *Am J Kidney Dis* 29: 829-842, 1997
8. Alamartine E, Sabatier J, Guerin C, Baerliet J, Berthoux F: Prognostic factors in mesangial IgA glomerulonephritis: An extensive study with univariate and multivariate analyses. *Am J Kidney Dis* 18: 12-19, 1991
9. Welch TR, McAdams AJ, Berry A: Rapidly progressing IgA nephropathy. *Am J Dis Child* 142: 789-793, 1988
10. Subias R, Botey A, Darnell A, Montoliu J, Revert L: Malignant or accelerated hypertension in IgA nephropathy. *Clin Nephrol* 27: 1-7, 1987
11. Shouno Y, Shimokama T, Sakemi T, Harada A, Yamaguchi M, Wantanabe T: Segmental glomerular necrosis as an active index of IgA nephropathy: A study with 100 serial sections of 128 cases. *Acta Pathol Jpn* 43: 723-729, 1993
12. Tumlin JA, Lohavichan V, Hennigar R: Crescentic proliferative IgA nephropathy: Clinical and histologic response to methyl prednisolone and intravenous cyclophosphamide. *Nephrol Dial Transplant* 18: 1321-1329, 2003
13. Tumlin JA, Hennigar R: Clinical presentation, natural history, and treatment of crescentic proliferative IgA nephropathy. *Semin Nephrol* 24: 256-268, 2006
14. Rifai A, Millard K: Glomerular deposition of immune complexes prepared with monomeric or polymeric IgA. *Clin Exp Immunol* 60: 368, 1985
15. Sano T, Hiki Y, Kokubo H, Iwase H, Shigematsu H, Kaboyashi Y: Enzymatically deglycosylated human IgA1 molecules accumulate and induce inflammatory cell reaction in rat glomeruli. *Nephrol Dial Transplant* 17: 50-56, 2002
16. Novak J, Vu HL, Novak L, Julian B: Interactions of human mesangial cells with IgA and IgA-containing immune complexes. *Kidney Int* 62: 465-475, 2006
17. Van der Boog PJM, van Kooten C, de Fijter JW: Role of macromolecular IgA in IgA nephropathy. *Kidney Int* 67: 813-821, 2006
18. Van der Boog PJ, van Kooten C, van Seggelen A, Mallat M, Klar-Mohamad N, de Fijter JW, Daha MR: An increased polymeric IgA level is not a prognostic marker for progressive IgA nephropathy. *Nephrol Dial Transplant* 19: 2487-2493, 2004
19. Van Es L: Pathogenesis of IgA nephropathy. *Kidney Int* 41: 1720-1729, 1992
20. Floege J, Feehally J: IgA nephropathy: Recent developments. *J Am Soc Nephrol* 11: 2395-2403, 2000
21. Allen AC, Bailey EM, Bencheley PE, Buck KS, Barratt J, Feehally J: Mesangial IgA1 in IgA nephropathy exhibits aberrant O-glycosylation: Observations in three patients. *Kidney Int* 60: 969-973, 2001
22. Hiki Y, Odani H, Takahashi M, Yasuda Y, Nishimoto A, Iwase H, Shinzato T, Kobayashi Y, Maeda K: Mass spectrometry proves under o-glycosylation of glomerular IgA1 in IgA nephropathy. *Kidney Int* 59: 1077-1085, 2001
23. Xu LX, Zhao MH: Aberrantly glycosylated serum IgA1 are closely associated with pathologic phenotypes of IgA nephropathy. *Kidney Int* 68: 167-172, 2005
24. Boyce NW, Holdsworth SR, Thomson NM, Atkins RC: Clinicopathological associations in mesangial IgA nephropathy. *Am J Nephrol* 6: 246-252, 1986
25. Sinniah R: Idiopathic IgA mesangial nephropathy: Histological features. *Contrib Nephrol* 40: 156-166, 1984
26. Chida Y, Tomura S, Takeuchi J: Renal survival rate of IgA nephropathy. *Nephron* 40: 189-194, 1985
27. D'Amico G, Napodano P, Ferrario F, Rastaldi MP, Arrigo G: Idiopathic IgA nephropathy with segmental necrotizing lesions of the capillary wall. *Kidney Int* 59: 692, 2001
28. Hisano S, Kiyoshi Y, Tanaka I, Tokieda K, Niimi K, Tsuru N, Takebayashi S, Iwasaki H: Clinicopathological correlation of childhood IgA glomerulonephritis presenting diffuse endocapillary proliferation. *Pathol Int* 54: 174-180, 2004
29. Tang Z, Wu Y, Wang QW, Yu YS, Hu WX, Yao XD, Chen HP, Liu ZH, Li LS: Idiopathic IgA nephropathy with diffuse crescent formation. *Am J Nephrol* 22: 480-486, 2002
30. Ferrario F, Napodano P, Rastaldi M, D'Amico G: Capillaritis in IgA nephropathy. *Contrib Nephrol* 111: 8-12, 1995
31. Abe T, Kida H, Yshimura H, Koshino Y, Tomosugi N, Hattori N: Participation of extracapillary lesions (ECL) in progression of IgA nephropathy. *Clin Nephrol* 25: 37-41, 1986
32. Widstam-Attorps U, Berg U, Bohman S, Lefvert A: Proteinuria and renal function in relation to renal morphology. *Clin Nephrol* 38: 245-253, 1992
33. Nicholls K, Walker R, Dowling J, Kincaid-Smith P: "Malignant" IgA nephropathy. *Am J Kidney Dis* 5: 42-46, 1985
34. D'Amico G, Minetti L, Ponticelli C, Fellin G, Ferrario F, Barbiano di Belgioioso G, Imbasciati E, Ragni A, Bertoli S, Fogazzi G: Prognostic indicators in idiopathic IgA mesangial nephropathy. *Q J Med* 59: 363-378, 1986
35. Schena F: A retrospective analysis of the natural history of primary IgA nephropathy worldwide. *Am J Med* 89: 209-215, 1990
36. Praga M, Gutierrez E, Gonzalez E, Morales E, Hernandez E: Treatment of IgA nephropathy with ACE inhibitors: A randomized and controlled trial. *J Am Soc Nephrol* 14: 1578-1583, 2003
37. Pozzi C, Andrulli S, Del Vecchio L: Corticosteroid effectiveness in IgA nephropathy: Long-term results of a randomized, controlled trial. *J Am Soc Nephrol* 15: 157-163, 2004
38. Kuriki M, Asahi K, Asano K: Steroid therapy reduces mesangial matrix accumulation in advanced IgA nephropathy. *Nephrol Dial Transplant* 18: 1311-1315, 2003
39. Donadio J, Bergstralh E, Offord K, Spencer D, Holley K: A controlled trial of fish oil in IgA nephropathy. *N Engl J Med* 331: 1194-1228, 1994
40. Appel GB, Waldman M: The IgA nephropathy treatment dilemma. *Kidney Int* 69: 1939-1944, 2006
41. Rasche FM, Keller F, Von Muller L, Sailer LK, Karges W, Czock D: Mycophenolate acid therapy after cyclophosphamide pulses in progressive IgA nephropathy. *J Nephrology* 19: 465-472, 2006
42. Hogg RJ, Lee J, Nardelli N: Clinical trial to evaluate omega-3 fatty acids and alternative day prednisone in patients with IgA nephropathy: Report from the Southwest Pediatric Nephrology Study Group. *Clin J Am Soc Nephrol* 1: 467-474, 2006

43. Kobayashi Y, Hiki Y, Kokubo T, Horii A, Tateno S: Steroid therapy during the early stage of progressive IgA nephropathy: A 10-year follow up study. *Nephron* 72: 237-242, 1996
44. Katafuchi R, Ikeda K, Mizumasa T: Controlled, prospective trial of steroid treatment in IgA nephropathy: A limitation of low dose prednisolone therapy. *Am J Kidney Dis* 41: 972-983, 2003
45. Lai K, Lai F, Ho C, Chan W: Corticosteroid therapy in IgA nephropathy with nephrotic syndrome: A long-term controlled trial. *Clin Nephrol* 26: 174-180, 1986
46. Ballardie FW, Roberts ISD: Controlled prospective trial of prednisolone and cytotoxics in progressive IgA nephropathy. *J Am Soc Nephrol* 13: 142-148, 2002
47. Roccatello D, Ferro M, Cesano G: Steroid and cyclophosphamide in IgA nephropathy. *Nephrol Dial Transplant* 15: 833-835, 2000
48. Tang S, Leung JCK, Chan LY: Mycophenolate mofetil alleviates persistent proteinuria in IgA nephropathy. *Kidney Int* 68: 802-812, 2005
49. Maes BD, Oyen R, Claes K: Mycophenolate mofetil in IgA nephropathy: Results of a 3 year prospective placebo-controlled randomized study. *Kidney Int* 65: 1842-1849, 2004
50. Harmankaya O, Ozturk Y, Basturk T, Obek A, Kihcarslan I: Efficacy of immunosuppressive therapy in IgA nephropathy presenting with isolated hematuria. *Int Urol Nephrol* 33: 167-171, 2002
51. Shoji T, Nakanishi I, Suzuki A: Early treatment with corticosteroids ameliorates proteinuria, proliferative lesions, and mesangial phenotypic modulation in adult diffuse proliferative IgA nephropathy. *Am J Kidney Dis* 35: 194-201, 2000
52. Hotta O, Furuta T, Chiba S, Tomioka S, Toguma Y: Regression of IgA nephropathy: A repeat biopsy study. *Am J Kidney Dis* 39: 493-502, 2003
53. McIntyre CW, Fluck RJ, Lambie SH: Steroid and cyclophosphamide therapy for IgA nephropathy associated with crescentic change: An effective treatment. *Clin Nephrol* 56: 193-198, 2001
54. Tsuruya K, Harada A, Hirakata H: Combination therapy using prednisolone and cyclophosphamide slows the progression of moderately advanced IgA nephropathy. *Clin Nephrol* 53: 1-9, 2000
55. Yoshikawa N, Ito H: Combined therapy with prednisolone, azathioprine, heparin-warfarin and dipyridamole for pediatric patients with severe IgA nephropathy: Is it relevant for adult patients? *Nephrol Dial Transplant* 14: 1097-1099, 1999
56. Samuels JA, Strippoli GF, Craig JC, Schena FP, Molony DA: Immunosuppressive treatments for immunoglobulin A nephropathy: A meta-analysis of randomized trials. *Nephrology* 9: 177-185, 2004
57. Waldo FB, Wyatt RJ, Kelly DR, Herrera GA, Benfield MR, Kohaut EC: Treatment of IgA nephropathy in children: Efficacy of alternate day oral prednisone. *Ped Nephrol* 5: 529-532, 1993
58. Haramaki R, Tamaki K, Fujisawa M, Ikeda H, Haramaki N, Okuda S: Steroid therapy and urinary transforming growth factor beta-1 in IgA nephropathy. *Am J Kidney Dis* 6: 1191-1198, 2001